



Original Research Article

Evaluation of root resorption after orthodontic treatment: A clinical study of contributory factors

Jasleen Kaur^{1,*}, Divya Shetty¹, Payal Sharma¹, Piush Kumar¹, Achint Juneja¹,
Monis Raza¹

¹Dept of Orthodontics and Dentofacial Orthopaedics, I.T.S Centre for Dental Studies and Research, Muradnagar, Ghaziabad, Uttar Pradesh, India



ARTICLE INFO

Article history:

Received 15-10-2020

Accepted 11-02-2020

Available online 23-11-2020

Keywords:

Root resorption

Fixed orthodontic treatment

forces

ABSTRACT

Introduction: The aim of this study was to evaluate the contributory factors of external apical root resorption.

Materials and Methods: Sixty subjects who had undergone complete orthodontic treatment were selected. The difference of the root length between pre and post-treatment was measured. The degree of root resorption was scored according to the index proposed by Levander and Malmgren.¹ The mean root resorption score (MRRS) was calculated. Mann Whitney test was done to compare the groups. Pearson correlation was applied.

Results: There was no statistically significant difference in root resorption among males and females. Tooth extraction was correlated with MRRS. Except for upper posterior teeth, the duration of treatment was positively correlated with MRRS. For overjet, there was a positive correlation between upper and lower anterior teeth and MRRS.

Conclusion: Orthodontic treatment should be carefully performed in patients who need extraction, great retraction of maxillary incisors and prolonged therapy.

© This is an open access article distributed under the terms of the Creative Commons Attribution License (<https://creativecommons.org/licenses/by/4.0/>) which permits unrestricted use, distribution, and reproduction in any medium, provided the original author and source are credited.

1. Introduction

During orthodontic treatment, the movement of the teeth occurs inside the bony socket. Application of force to the teeth and their periodontium leads to remodelling of bone and cementum which helps in correcting the position and the malocclusion.^{2,3}

External apical root resorption is defined as surface resorption with loss of cementum that is irreversible when involving dentin.^{4,5} It is one the most common and undesirable iatrogenic effect of orthodontic treatment.^{2,6,7} It occurs when the pressure on the cementum surpasses the reparative capacity of its cellular structures, exposing the dentine to activated odontoclasts causing irreversible loss of root structure.^{8,9} Root resorption begins near hyalinised

tissues. And, its pathogenesis is associated with the removal of the necrotic tissue from the periodontium that gets compressed by orthodontic forces.^{9,10}

The normal function of a tooth is unaffected in mild cases of external apical root resorption, but in severe cases of external apical root resorption, orthodontic treatment should be stopped immediately as it allows the cementum to heal.^{3,8}

Several studies have been done to find the contributory factors associated with external apical root resorption but still, it is difficult to predict whether the patient will develop it or not^{11,12} The factors associated with apical root resorption, due to orthodontic treatment, can be either patient-specific or treatment specific.^{7,10} Severe resorption is considered to be a loss of more than 4 mm or more than one-third overall root length and affects 15% of orthodontically treated patients.^{9,13}

* Corresponding author.

E-mail address: jasleenkaur_mds18_21@its.edu.in (J. Kaur).

Knowing the etiology of external apical root resorption would allow the clinicians to predict the incidence, location and severity of root resorption before the commencement of orthodontic treatment.¹⁴

Orthodontists are still continuously concerned about this situation, so the present study was aimed to evaluate the patient-related and treatment-related factors of external apical root resorption. Thus, the following study was conducted to evaluate the patient-related and treatment-related factors of external apical root resorption, to score the root resorption level in the subjects and to assess the risk factors of external apical root resorption.

2. Methods and Materials

The study was conducted in the Department of our institute in India.

2.1. Sample selection

Sixty patients (30 males and 30 females) who had undergone fixed appliance orthodontic therapy were selected according to the following criteria: complete records of the patients including pre and post-treatment panoramic radiographs and no relevant medical history in the past. Patients excluded were those who had undergone orthognathic surgery, cleft lip/palate patients, low-quality radiographs, history of systemic illness, history of tooth injury, history of impacted teeth or history of parafunctional habits.

2.2. Examination of records

Pre-treatment data were recorded including gender, age at the start of treatment, overjet, type of treatment (extraction or non-extraction) and treatment duration.

2.3. Examination of panoramic radiographs

Standardized Pre and Post-treatment panoramic radiographs of 60 patients were analysed. Root lengths of all maxillary and mandibular teeth from central incisors to first permanent molars were measured on the pre and post-treatment radiographs of all patients.

2.4. Root resorption measurement

A Digital Vernier calliper with an accuracy of 0.01 was used for measuring root length. Tooth length was measured as the distance from the root apex to the midpoint of the incisal edge or cusp tip. (Figures 1 and 2) Root resorption was calculated by the difference of the tooth length between the pre and post-treatment measurements. The tooth length was measured for the left and right central incisors, lateral incisors, premolars and first molars on both jaws.

The degree of external apical root resorption (EARR) was scored according to the index proposed by Levander

and Malmgren¹ (Figure 3), using a 0 – 4 scale of severity, as follows:

Score 0: Absence of changes in the root apex

Score 1: Irregular root contour

Score 2: EARR of less than 2 mm

Score 3: EARR from 2 mm to one-third of the original root length

Score 4: EARR exceeding one-third of original root length

The mean root resorption score (MRRS) for every patient was calculated for four segments in each patient: upper anterior, upper posterior, lower anterior and lower posterior teeth, using the formula.⁶

$$\text{Mean root resorption score} = \frac{\text{Sum of the scores}}{\text{Number of teeth}}$$

2.5. Statistical analysis

Statistical analysis was performed using the Statistical Package for the Social Sciences computer software (SPSS version 16.0) to analyse the data. Significance level was fixed as 5% ($\alpha = 0.05$). Shapiro-Wilks test was carried out to assess the normality of variables in the study. Descriptive statistics were performed for root resorption values recorded in groups. Mann Whitney U test was used to compare root resorption levels between male and female, and extraction and non-extraction cases. Bivariate correlation and analysis were undertaken between the type of therapy, duration, overjet, and MRRS after treatment. Using the MRRS as the dependent variable, and age, gender, type of therapy, overjet and duration of treatment as independent variables, multiple regression analysis was done.

2.6. Method error

The same observer performed all assessments of root resorption. Twenty patients were randomly selected and panoramic radiographs before and after orthodontic treatments were measured by the same examiner after a 10-day interval to determine reliability. The intra-class correlation coefficient between the 2 examinations was 0.93. The difference between the first and second measurements was not significant (Table 1).

3. Results

3.1. Demographic data

39 patients were treated with extraction and 21 without extraction. The average age of males was 16.05 ± 2.6 years and of females was 15.2 ± 3.5 years at the initiation of the treatment.

MRRS score was more in extraction cases as compared to non-extraction cases. Upper anterior teeth had more MRRS scores as compared to other teeth in both extraction and non-extraction cases (Table 2). Root resorption was compared on the basis of gender using the Mann Whitney

U test. Since the P-value was more than 0.05, there was no statistically significant difference in root resorption among males and female cases. (Table 3) Root resorption was also compared between extraction and non-extraction groups using the Mann Whitney U test. There was a statistically significant difference present between the two groups. ($P < 0.05$) (Table 4). Tooth extraction had a statistically significant correlation with the mean root resorption score. Except for upper posterior teeth, the duration of orthodontic treatment was positively correlated with MRRS. For overjet, there was a statistically significant correlation with upper anterior and lower anterior teeth MRRS (Table 5). MRRS was used as the dependent variable and age, gender, overjet, type of treatment (extraction or non-extraction) and duration of the treatment were taken as independent variables.

All factors, except age and gender, had a statistically significant correlation with root resorption. Treatment type had a positive correlation with root resorption upper anterior and lower posterior teeth. Treatment duration was correlated with upper and lower anterior teeth root resorption. Over jet had a correlation with the resorption of upper anterior teeth only (Table 6).

4. Discussion

External apical root resorption is a common side effect of orthodontic treatment. It is a sterile, local inflammatory process that induces shortening of the roots and weakening of teeth.^{4,15} It has a multifactorial etiology. It might be occurring due to individual biology and the effects of mechanical factors. Root resorption is considered as clinically important when 1-2 mm of length is lost. Severe root resorption during orthodontic treatment (>5 mm) occurs very rarely just in 5% of patients.¹

The mechanism of root resorption is not completely explored. According to Brudvik and Rygh, inflammatory root resorption induced by orthodontic treatment is a part of the process of elimination of hyaline zone.¹⁶ It is considered that the occurrence of root resorption can be induced by the strong force through orthodontic treatment and hyalinization of periodontal ligament induced by increased activity of cementoclasts, osteoclasts. During tooth movement, areas of compression, where osteoclasts are inducing bone resorption and areas of tension where osteoblasts are inducing bone deposition are formed. Thus, a tooth moves towards the side of bone resorption. Any imbalance between bone resorption and deposition results in loss of protective characteristic of cementum which may contribute to the osteoclastic activity, resorbing areas of the root. Tooth root surface under the hyaline zone resorbs.^{10,16,17}

Several studies have been done to find the contributory factors associated with external apical root resorption.^{4,9,11,15} Patient-specific factors can be age, gender, type of malocclusion, oral habits like thumb

sucking, genetics, the shape of the root, bone morphology, etc. Treatment-specific factors include extractions, the orthodontic technique used, treatment duration, amount and direction of force applied, type of tooth movement etc.^{4,7,10,11,13}

The clinical diagnosis of root resorption is based mainly on routine radiographic procedures, such as periapical radiography, panoramic radiography, CBCT and CT scans. Periapical radiographs are widely used in dentistry, but however limited in their coverage of the maxilla-mandibular structures and multiple films are needed for a comprehensive examination.⁶ Periapical films are accurate and localised but the amount of radiation exposure, a patient is subjected to, increases.¹

Conventional extra-oral radiographs such as the lateral cephalogram can achieve better coverage, but anatomical structures of the facial skeleton that are not in the midline cannot be measured accurately because of distortion. Bilateral structures produce two images and it is difficult to differentiate between right and left sides.^{6,7}

A panoramic radiograph is another commonly used radiograph that has overcome many limitations of extraoral radiography including controlled magnification in the vertical dimension, decreased overlapping of tooth contact areas and single point contact of the rotating beam onto the object to allow for a sharper, well-defined image. Panoramic radiographs are advantageous as the information of all teeth, dento-alveolar bone and jaws can be taken from a panoramic film.

CT scans and CBCT provide more accurate three-dimensional images of teeth.⁷ However it has got limitations compared to conventional radiographs, which includes increased cost and amount of radiation. The effective dose of CBCT is 1.5 to 3.3 times higher than that associated with panoramic radiographs.

Therefore, in the present study, panoramic radiography was used for measuring root resorption because of three main reasons. They are:

1. A panoramic film is routinely ordered as the primary pre-treatment and post-treatment radiograph.
2. Less radiation exposure, less chairside time, less operator time and better patient co-operation.
3. Panoramic radiographs have the added advantage of displaying the entire maxilla-mandibular region on a single film. It provides increased coverage of the dental arches and associated structures, relatively undistorted anatomic images, reduced radiation dosage for the patient and simplicity of operation.

There are two methods to assess root resorption: one that measures the length of the root directly to determine the amount of root resorption, the other marks the degree of root resorption.⁶ In this study, the difference between the total tooth length was measured for evaluating the amount

of root resorption. The same method was used by Jung et al.,¹⁷

In this study, apical root resorption was classified according to widely accepted index proposed by Levander and Malmgren.¹ This method has been used in many root resorption studies performed after orthodontically induced tooth movement. This method does not depend on standardization of initial radiographs.^{1,13}

In the present study, the factors associated with external apical root resorption were treatment involving extractions, longer treatment duration and greater overjet at the initiation of treatment. It was difficult to compare the prevalence and extent of external apical root resorption in our study with that of other studies because of the variations of methods and techniques employed. In this study, there was no statistically significant difference in root resorption among males and females. This is in contradiction to the results of studies done by Spurrier and Hall⁶ who found females had more resorption than males. But it is in agreement with studies done by Linge and Linge, Jiang et al., and Jung et al.^{6,17}

According to Linge and Linge, external apical root resorption was dependent on age. They found out that patients starting treatment after 11 years of age experienced significantly more root resorption than those starting earlier. The concept was that the root resorption increases with age because of reduced ability to repair root resorption in older patients.^{6,14} But it is disapproved by Jung et al., and Han et al.^{17,18} This study also showed no relationship between root resorption and the age of the patient.

In our study, anterior maxillary teeth proved more likely to present higher mean root resorption scores in both the extraction (0.44 ± 0.21) and the non-extraction (0.40 ± 0.19) groups than the teeth located in the mandibular arch. A similar finding was found in other studies.^{13,17} Few studies^{17,19,20} found that the maxillary central incisors were the most resorbed, with 27% undergoing greater than 1 mm of root resorption and premolars and canines were relatively unaffected. Proximity between the roots of maxillary central incisors and the cortical bone of the socket, the incisive canal and the alveolar bone on the buccal surface, combined with the type of movement may explain the higher incidence of severe root resorption these teeth.¹³ Whereas in mandibular arch, the extraction space is usually used to relieve the crowding, so, the incisors might not be submitted to major retraction.¹⁴

According to the present study, the treatment duration (mean: 20.36 ± 6.2 months) was significantly correlated with external apical root resorption. This was in agreement with other studies,^{3,6,13,14,17} although Linge and Linge¹⁵ did not agree with this finding. Difficult treatment plans, appointment intervals and poor patient compliance act as confounding factors and increase the treatment duration which is related to external apical root resorption.^{17,13}

In this study, the average treatment duration in the extraction group was 24 ± 4.2 months, longer than in the non-extraction group (14.4 ± 4.2 years). Also, the extraction group showed more external apical root resorption in comparison with the non-extraction group. According to Sharpe et al., the incidence of external root resorption was 3.72 times higher in the extraction group than the non-extraction group.¹⁷ This can be due to the longer treatment time needed for finishing orthodontic treatment. It is assumed that the extraction of teeth could increase the amount of movement and treatment duration.^{13,17} After doing multiple regression correlation analysis, the resorption of the upper anterior and lower posterior had a positive correlation with extraction cases ($P < 0.01$).

Overjet had a positive correlation with external apical root resorption in maxillary and mandibular anterior teeth in the present study. This can be because of the correction of large overjet. This finding can also be seen in some studies.¹³⁻¹⁵ To correct large overjet, anterior teeth were moved long distances to reduce maxillary anterior protrusion and active torque with rectangular wires was also given, which resulted in external apical root resorption. but, according to Jung et al., there was no correlation between the overjet and root resorption.¹⁷

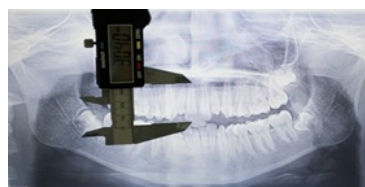

Fig. 1: Pre-treatment tooth length

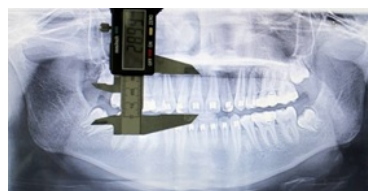

Fig. 2: Post-treatment tooth length




Fig. 3: Root resorption score Index - Levander and Malmgren

This study suggests that the orthodontic treatment should be carefully performed in patients who need an extraction,

Table 1: Intra class correlation coefficient

	Intra class correlation	95% Confidence Interval		F Test with true value 0			
		Lower bound	Upper bound	Value	df1	df2	Sig
Single Measures	.939	.906	.960	31.623	79	79	.000
Average Measures	.968	.951	.980	31.623	79	79	.000

Table 2: Average MRRS for different segments among extraction and non-extraction cases

	Upper anterior	Upper posterior	Lower anterior	Lower posterior
Non-extraction cases	0.40±0.19	0.11±0.15	0.23±0.25	0.04 0.04±0.07
Extraction cases	0.44±0.21	0.18±0.17	0.24±0.20	0.18±0.16

Table 3: Mann Whitney U test comparing MRRS among males and females.

MRRS	Upper anterior	Upper posterior	Lower anterior	Lower posterior
Mann-Whitney U	409.500	417.500	395.000	339.000
Z	-.622	-.514	-.845	-1.760
P value	.534	.607	.398	.078

a. Grouping variable: Gender

Table 4: Mann Whitney U test comparing Root resorption on the basis of the type of treatment.

MRRS	Upper anterior	Upper posterior	Lower anterior	Lower posterior
Mann-Whitney U	31.000	293.000	118.500	174.000
Z	-6.092	-1.931	-4.687	-3.914
P value	.000	.054	.000	.000

b. Grouping variable: Type

Table 5: Correlation coefficients of the bivariate correlation analysis between treatment type, duration, overjet and mean root resorption score after treatment for the upper and lower anterior and posterior teeth

Correlation coefficient	MRRS Upper anterior	MRRS Upper posterior	MRRS Lower anterior	MRRS Lower posterior
Type	0.802**	0.262*	0.585**	0.467**
Duration	0.819**	0.201	0.722**	0.296*
Overjet	0.502**	0.018	0.341**	0.159

**P<0.01 *P<0.05

Table 6: Correlation coefficients of the multiple regression analysis of MRRS

	Upper anterior	Upper posterior	Lower anterior	Lower posterior
Gender	-0.08	0.04	-0.09	0.09
Age	-0.04	0.12	0.07	-0.13
Type	0.39**	0.25	0.05	0.578**
Duration	0.43**	0.07	0.64**	-0.15
Overjet	0.23**	-0.09	0.14	-0.39

greater retraction of maxillary incisors and prolonged therapy.

5. Conclusion

External apical root resorption is a relatively common iatrogenic outcome of orthodontic treatment, which can be seen in routine panoramic radiographs. Age and gender were not an influencing factor in root resorption. Overjet and overbite had a statistically significant correlation with

post-treatment root resorption. There was a statistically significant difference between extraction and non-extraction groups for root resorption. There was a statistically significant correlation between treatment duration and the amount of root resorption: the longer the duration, the more severe the root resorption. Overjet greater than or equal to 5 mm had a statistically significant correlation with external apical root resorption.

6. Source of Funding

None.

7. Conflict of Interest

None.

References

1. Levander E. Early radiographic diagnosis of apical root resorption during orthodontic treatment: a study of maxillary incisors. *Eur J Orthod.* 1998;20(1):57–63.
2. Pastro JDV, Nogueira ACA, Defreitas KMS, Valarelli FP, Cançado RH, Oliveira RCGD, et al. Factors Associated to Apical Root Resorption after Orthodontic Treatment. *Open Dent J*;2018:331–9.
3. Roscoe MG, Meira JBC, Cattaneo PM. Association of orthodontic force system and root resorption: A systematic review. *Am J Orthod Dentofacial Orthop.* 2015;147(5):610–26.
4. Brezniak N, Wasserstein A. Orthodontically Induced Inflammatory Root Resorption . Part I : The Basic Science Aspects. *Angle Orthod.* 2002;72(2):175–9.
5. Brezniak N, Wasserstein A. Root resorption revisited: The paradigm of force effect on root resorption: Is a ‘paradigm shift’ needed in order to learn more about the phenomenon? *Angle Orthod.* 2019;89(3):518–20.
6. Jiang RP, McDonald JP, Fu MK. Root resorption before and after orthodontic treatment: a clinical study of contributory factors. *Eur J Orthod.* 2010;32(6):693–7.
7. Samandara A, Papageorgiou SN, Marathiotou LL, Tsatala SK, Papadopoulos MA. Evaluation of orthodontically induced external root resorption following orthodontic treatment using cone beam computed tomography (CBCT): a systematic review and meta-analysis. *Eur J Orthod.* 2019;41(1):67–79.
8. Lee YJ, Lee TY. External root resorption during orthodontic treatment in root-filled teeth and contralateral teeth with vital pulp: A clinical study of contributing factors. *Am J Orthod Dentofacial Orthop.* 2016;149(1):84–91.
9. Currell SD, Liaw A, I Grant PDB, Esterman A, Nimmo A. Orthodontic mechanotherapies and their influence on external root resorption: A systematic review. *Am J Orthod Dentofacial Orthop.* 2019;155(3):313–329.
10. Savoldi F. Incisal Apical Root Resorption Evaluation after Low-Friction Orthodontic Treatment Using Two-Dimensional Radiographic Imaging and Trigonometric Correction. *J Clin Diagn Res.* 2015;9(11):70–4.
11. Decastilhos BB, Desouza CM, Fontana M, Pereira FA, Tanaka OM, Trevilatto PC, et al. Association of clinical variables and polymorphisms in RANKL, RANK, and OPG genes with external apical root resorption. *Am J Orthod Dentofac Orthop.* 2019;155(4):529–42.
12. Handem RH, Janson G, Matias M, Defreitas KMS, Delima DV, Garib DG, et al. External root resorption with the self- ligating Damon system-a retrospective study. *Prog Orthod.* 2016;17(1):20.
13. Maués CPR, Nascimento RRD, Vilella ODV. Severe root resorption resulting from orthodontic treatment: Prevalence and risk factors. *Dent Press J Orthod.* 2015;20(1):52–8.
14. Nanekrungsan K, Patanaporn V, Janhom A, Korwanich N. External apical root resorption in maxillary incisors in orthodontic patients: associated factors and radiographic evaluation. *Imaging Sci Dent.* 2012;42(3):147–54.
15. Linge BO, Linge L. Apical root resorption in upper anterior teeth. *Eur J Orthod.* 1983;5(3):173–83.
16. Kurol J, Mall PO. Hyalinisation and root resorption during early orthodontic tooth movement in adolescents. *Angle Orthod.* 1998;68(2):161–66.
17. Jung YH, Cho BH. External root resorption after orthodontic treatment : a study of contributing factors. *Imaging Sci Dent.* 2011;41(1):17–21.
18. Han J, Hwang S, Nguyen T, Proffit WR, Soma K, Choi YJ, et al. Periodontal and root changes after orthodontic treatment in middle-aged adults are similar to those in young adults. *Am J Orthod Dentofacial Orthop.* 2019;155(5):650–5.
19. Barros SE, Janson G, Chiqueto K, Baldo VO, Baldo TO. Root resorption of maxillary incisors retracted with and without skeletal anchorage. *Am J Orthod Dentofacial Orthop.* 2017;151(2):397–406.
20. Dealmeida RM, Marcal ASB, Fernandes TMF, Vasconcelos JB, Dealmeida RR, Nanda R, et al. A comparative study of the effect of the intrusion arch and straight wire mechanics on incisor root resorption : A randomized , controlled trial. *Angle Orthod.* 2018;88:20–26.

Author biography

Jasleen Kaur, PG Student

Divya Shetty, Professor

Payal Sharma, Professor & HOD

Piush Kumar, Professor

Achint Juneja, Professor

Monis Raza, Sr. Lecturer

Cite this article: Kaur J, Shetty D, Sharma P, Kumar P, Juneja A, Raza M. Evaluation of root resorption after orthodontic treatment: A clinical study of contributory factors. *J Dent Spec* 2020;8(1):3-8.